

# Magnetic resonance imaging of hypothenar hammer syndrome: Case series

Hypotenar hammer syndrome

Onur Karacif<sup>1</sup>, Aynur Turan<sup>1</sup>, Meltem Özdemir<sup>1</sup>, Egemen Ayhan<sup>2</sup>  
<sup>1</sup>Radiology Department, <sup>2</sup>Department of Hand Surgery,  
Medical Sciences Univesity, Diskapi Yıldırım Beyazıt Health Application and Research Center, Ankara, Turkey

### Abstract

Hypothenar hammer syndrome is observed in some occupational groups or some athletes who use objects that can cause recurrent trauma to the superficial palmar region of their ulnar artery by the object they handle. The advance in imaging technologies and the increased use of these methods significantly raised the importance of MRI as well as MR angiography in evaluating wrist pathologies. Presenting these cases we aimed to discuss the MR imaging findings of hypothenar hammer syndrome. HHS is a treatable and preventable cause of the upper extremity digital ischemia. Radiologists should keep HHS in mind as a differential in the cases presenting with hand and finger symptoms, especially the ones in risk groups.

### Keywords

Ulnar Artery Aneurysm; Hand Pain; Ulnar Artery Thrombosis

DOI: 10.4328/ACAM.6059 Received: 22.10.2019 Accepted: 03.01.2019 Publihed Online: 05.01.2019 Printed: 01.11.2019 Ann Clin Anal Med 2019;10(6): 761-4  
Corresponding Author: Onur Karacif, Sağlık Bilimleri Üniversitesi, Dışkapı Yıldırım Beyazıt SUAM Radyoloji Bölümü, 06010, Ankara, Turkey.  
T.: +90 3125962478 E-Mail: onurkaracif@gmail.com

Introduction

Pain in fingers and hands is a frequent cause of admission to hospitals. These symptoms are associated with musculoskeletal overuse syndrome secondary to sportive and occupational activities. In rare instances, various vascular conditions or traumatic injury can explain this symptomatology. Although hypotenar hammer syndrome (HHS) is a well-known clinical syndrome by experts, it is a clinical entity which is not well known in daily radiological practice. The trauma to the superficial palmar region of the ulnar artery is caused by handling objects that can cause trauma to the palmar face of the hand during occupational or sporting activities[1].

The differential diagnosis is very wide due to the complex anatomy of this region[1, 2]. Although the gold standard for the diagnosis is conventional angiography [3], thanks to technological advances, MRI has become an indispensable part of these pathologies. In this article, we aim to discuss the clinical features, pathogenesis, diagnosis, and imaging of HHS.

Case Report

Case 1: A 39-year-old shoe repairer without a previously known disease admitted to the hand surgery outpatient clinic with the complaint of pain in the fingers of his left hand, and was referred to the department of radiology for a wrist MRI. Aneurysmatic dilatation, diffuse wall thickening reaching up to 4 mm and intraluminal signal void loss suggestive of slow flow-thrombosis in the ulnar artery and superficial palmar arc of the wrist were observed on the contrast-enhanced left wrist MRI. In addition, a ganglion cyst extending from the level of intercarpal joints to the dorsal was noted. Further, CT angiography of the left upper extremity confirmed the findings of MRI, and the patient was diagnosed as having HHS.

Case 2: A 42-year-old mechanic worker who has been suffering from a pain in his left hand and arm, and tingling on the 4-5th fingers of his left hand for the last 6 months admitted to the hand surgery outpatient clinic. He had no previously known disease. On the physical examination, there were hypoesthesia and heat loss in the 4-5th fingers. In addition, swelling of the hypotenar area was detected. MRI showed aneurysmal dilatation and thrombosis of the superficial palmar arch of the ulnar artery on hypotenar region.

Case 3: A 59-year-old gardener who has been suffering from pain and swelling in the hypotenar region of his left hand for the last 6 months admitted to hand surgery outpatient clinic. The patient declared that he has not been working for the last 5 years. The patient was followed-up for hypertension, hyperlipidemia, and diabetes mellitus. He had a history of by-pass operation before his admittance. On the physical examination, swelling and mass-like appearance in the hypotenar region, and hypoesthesia in the 4-5th fingers of the left hand were observed. Furthermore, the ulnar pulse on the left hand could not be palpated. MRI revealed aneurysmatic dilatation and thrombosis of the ulnar artery. MRI findings were confirmed by Doppler US, and the final diagnosis was HHS.

Discussion

This clinical feature of HHS was first described by Guttani and Von Rosen. Identifying that repetitive blunt trauma to the hypo-

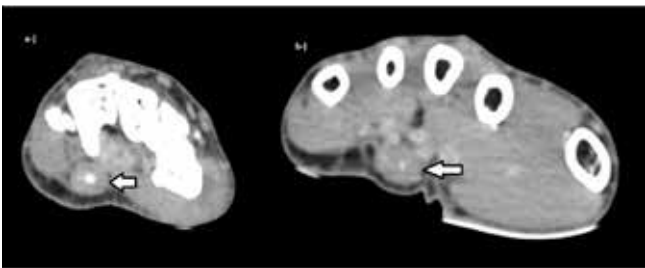


Figure 1. Proksimal part of Ulnar artery (arrow) (a). Distal part of ulnar artery and trombosis (arrow) (b).

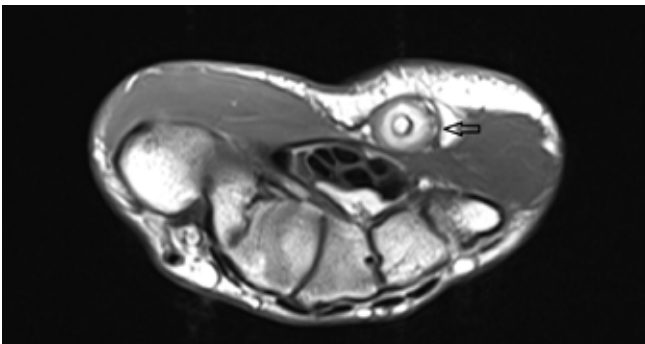


Figure 2. Axial T1 weighted imaging showing us aneurysmatic dilatation of ulnar artery (arrow).

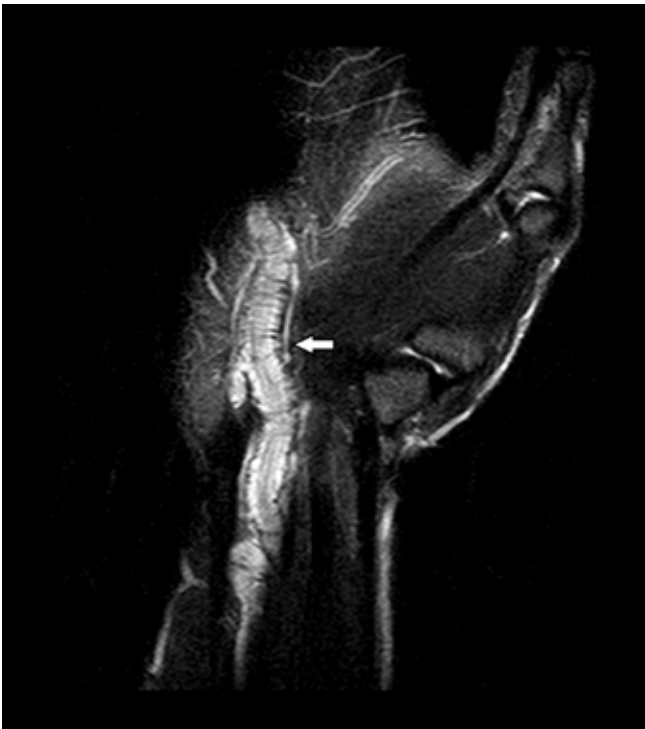

Figure 3. Coronal STIR image showing us aneurysmatic dilatation of Ulnar artery and lose of signal void (arrow).

thenar section of the hand could lead to ulnar artery damage, Conn et al. used the term “hypotenar hammer syndrome” in 1970 [1].

Although it is generally described as a rare condition, HHS is thought to be more frequent than predicted. It usually occurs in people who use the palmar face of the hand for professional and sportive activities. A similar clinical definition is the hand vibration syndrome. This is a complex syndrome involving vessels, nerves, muscles and joints resulting from the prolonged use of pneumatic hammers, chainsaws, impact switches, and other power tools that produce vibration[4].

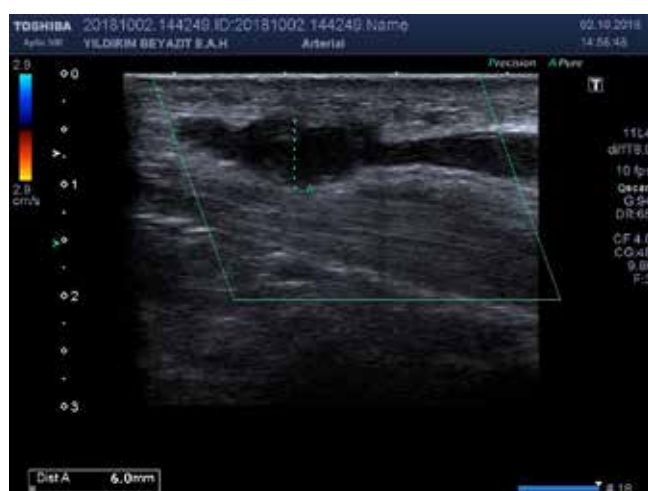

Figure 4. Doppler US imaging of the thrombosed superficial palmar branch.

The clinical presentation of HHS can be seen with intermittent findings and symptoms that appear following trauma. Typically, ischemia of the second, third, fourth or fifth fingers of the dominant hand develops in male patients [5].

The ulnar artery provides blood flow to the majority of the fingers. On the opposite side, it combines with radial indicis and princeps pollicis artery to form a superficial palmar arch. However, there are many variations in this combination. Because of this variable anatomy, clinical findings of HHS present a wide spectrum varying between an indolent course and digital infarction [6,7].

There are few reports concerning the incidence of HHS. The prevalence of this condition is estimated to be 14% in the risk groups [8].

In the HHS, the ulnar artery segment of over 2 cm which lies immediately distal to the Guyon canal before reaching the palmar aponeurosis, is the damaged segment. This segment of the ulnar artery is susceptible to injury due to its superficial location and limited protection of the soft tissues overlying it [9,10]. Repeated blunt trauma may induce intimal damage to the vasospasm in the superficial palmar segment of the ulnar artery and trigger platelet aggregation and thrombus formation. If the damage spreads from the media layer to the artery wall, aneurysm formation may occur. Neurological symptoms, such as paresthesia and pain, can be caused by the compression of the sensory branches of the ulnar nerve at close distance to the ulnar artery [10].

Digital ischemia can occur due to a number of reasons such as vasculitis, thromboangiitis obliterans, secondary thrombosis, atherosclerosis and thoracic outlet syndrome [11]. As exemplified in the case reports described above, HHS secondary to occupational and sportive overuse can be added to this differential diagnosis list as a rare cause.

For the differential diagnosis of HHS, osteoid osteoma, benign tumors of the hand (mostly lipomas, schwannomas and vascular malformations), malign tumors (more rare than benign tumors), ganglion cysts, tendinopathies in adjacent tendinous structures, arthropathy and triquetral-pisiform articulation disorders, hamatum fracture, Guyon Channel can be considered [12].

The Allen test may be useful for evaluating ulnar artery patency when evaluating for HHS, however, it is reported to be normal in 14% of cases [6].

For radiological evaluation of the patients who are suspected of having HHS, conventional radiography is the initial imaging method. Radiographic study should include posteroanterior, lateral and carpal tunnel images. By radiography, osseous anomalies such as hamatum fractures and arthropathies can be diagnosed [13].

Doppler US is a relatively inexpensive, non-invasive and easily available method for screening the patency and aneurysmatic dilatation of the ulnar artery. In addition to the evaluation of the patency, it also provides information on hemodynamic changes at this level. However, the technique requires expertise and is operator dependent. Doppler US can be considered as a screening tool rather than a diagnostic method for HHS [3].

The gold standard for establishing the diagnosis is conventional angiography [3].

MRI and MR angiography (MRA) provide a comprehensive assessment of the hypothenar region. MRI can be used to assess osteochondral, nervous, vascular, tendinous and ligamentous structures. The corkscrew appearance which is formed as the ulnar artery exits the Guyon duct, can be seen even on non-contrast MRI. MRA can show the areas of the segmental obstruction of the ulnar artery as well as the abnormal areas of the superficial palmar arch and common volar digital arteries. Although the spatial resolution of MRA is lower than that of conventional angiography, it is sufficient for surgical planning [12].

For the treatment of patients with HHS, both non-surgical and surgical approaches are available. Non-surgical treatment choice includes avoidance of further trauma, calcium channel blockers and anticoagulation [14, 15]. Surgical resection, ligation, and grafting can be used in complicated cases [16, 17].

### Conclusion

HHS may not be very rare, as previously estimated. It is a treatable and preventable cause of the upper extremity digital ischemia. Radiologists should keep HHS in mind as a differential in the cases presenting with hand and finger symptoms, especially in those with suspected occupational and sports history. When this clinical entity is suspected, a faster directing the patient to a hand surgeon would provide the opportunity to apply the appropriate treatment before persistent symptoms appear. In addition, considering the fact that in most patients this vascular injury is missed, regular screening of the hands of individuals in the occupations and sports in the risk group may be considered.

### Scientific Responsibility Statement

*The authors declare that they are responsible for the article's scientific content including study design, data collection, analysis and interpretation, writing, some of the main line, or all of the preparation and scientific review of the contents and approval of the final version of the article.*

### Animal and human rights statement

*All procedures performed in this study were in accordance with the ethical standards of the institutional and/or national research committee and with the 1964 Helsinki declaration and its later amendments or comparable ethical standards. No animal or human studies were carried out by the authors for this article.*

**Conflict of interest**

**None of the authors received any type of financial support that could be considered potential conflict of interest regarding the manuscript or its submission.**

**References**

1. Ablett CT, Hackett LA. Hypothenar Hammer Syndrome: Case Reports and Brief Review. *Clinical Medicine & Research*. 2008; 6(1): 3-8.
2. Muniz de Queiroz MM, Pachêco Pereira L, Gondim Picanço C, de Castro Luna R, da Silva Costa F, Régis Sampaio Silveira C. Hypothenar hammer syndrome: case report and literature review. *Rev Bras Ortop*. 2013; 48: 104-7.
3. Abdel-Gawad EA, Bonatti H, Housseini AM, Maged IM, Morgan RF, Hagspiel KD. Hypothenar hammer syndrome in a computer programmer: CTA diagnosis and surgical and endovascular treatment. *Vasc Endovascular Surg*. 2009; 43: 509-12.
4. Estermann L, Ducommun P, Steurer-Dober I, Hug U. Hypotenar Hammer Syndrome: caused by a muscle anomaly? A case report with review of the literature. *Arch Orthop Trauma Surg*. 2018; 138: 739.
5. Şahin MŞ, Özyüreköğlu T, Çakmak G. Hypothenar hammer syndrome: a case series and literature review. *Eklem Hastalıkları Cerrahisi*. 2015; 26(1): 11-15.
6. Yuen JC, Wright E, Johnson LA, Culp WC. Hypothenar hammer syndrome. *Ann Plast Surg*. 2011; 67: 429-38.
7. Swanson KE, Bartholomew JR, Paulson R. Hypothenar hammer syndrome: a case and brief review. *Vasc Med*. 2012; 17: 108-15.
8. Orrapin S, Arworn S, Wisetborisut A. Unusual Cases of Hypothenar Hammer Syndrome. *Annals of Vascular Diseases*. 2015; 8(3): 262-4.
9. Karaarslan AA, Karakaşlı A, Mayda A, Karcı T, Aycan H, Kobak Ş. Traumatic Distal Ulnar Artery Thrombosis. *Case Reports in Orthopedic*. 2014; DOI:10.1155/2014/983160.
10. Swofford BP, Swofford DP. Management of Hypothenar Hammer Syndrome: A Case Report. *The American Journal of Case Reports*. 2018; 19: 150-2.
11. McMahan ZH, Wigley FM. Raynaud's phenomenon and digital ischemia: a practical approach to risk stratification, diagnosis and management. *International journal of clinical rheumatology*. 2010; 5(3): 355-70.
12. Kumar Y, Hooda K, Lo L, Karol I. Ulnar artery aneurysm and hypothenar hammer syndrome. *BMJ Case Reports*. 2015; DOI:10.1136/bcr-2015-211444.
13. Blum AG, Zabel JP, Kohlmann R, Batch T, Barbara K, Zhu X, et al. Pathologic conditions of the hypothenar eminence: evaluation with multidetector CT and MR imaging. *Radiographics*. 2006; 26: 1021-44.
14. Marie I, Herve F, Primard E, Cailleux N, Levesque H. Long-term follow-up of hypothenar hammer syndrome: a series of 47 patients. *Medicine (Baltimore)*. 2007; 86: 334-43.
15. Zayed MA, McDonald J, Tittley JG. Hypothenar hammer syndrome from ice hockey stick-handling. *AnnVascSurg*. 2013; 27: 1183.
16. Kreitner KF, Duber C, Muller LP, Degreif J. Hypothenar hammer syndrome caused by recreational sports activities and muscle anomaly of the wrist. *Cardio-vasc Intervent Radiol*. 1996; 19: 356-9.
17. Wiecezorek I, Farber A, Alexander K. Hypothenar hammer syndrome successfully managed with intravenous prostaglandin E1 and heparin and with correction of the thrombogenic risk profile. *Angiology*. 1996; 47: 1111-116.

**How to cite this article:**

Karacif O, Turan A, Özdemir M, Ayhan E. Magnetic resonance imaging of hypothenar hammer syndrome: Case series. *Ann Clin Anal Med* 2019;10(6): 761-4.